www.uroleb.org

LEBANESE UROLOGY SOCIETY
الجمعية اللبنانية للمسالك البولية

LUS newsletter

Issue #33 - June 2022

Let's join the online world.
ننطلق في العالم الرقمي.

LEBANESE UROLOGY SOCIETY
الجمعية اللبنانية للمسالك البولية

uroleb.org

Let's join the online world.

Facebook page
https://www.facebook.com/LUS_LB

Instagram account
https://www.instagram.com/lus_lb/

Twitter account
https://twitter.com/LUS_lb

Thank you for the previous committee, headed by Prof. Pierre Sarkis for all the achievements that were done, maintaining the core mission and vision of LUS with the great board team: Mohamad Moussa MD, Zareh Kassardjian M.D., Khalil Armache M.D., Chady Waked M.D., Imad Farhat M.D., Alain Khalaf M.D., Wael Ghandour M.D., Wissam Abdel Samad M.D..

The Executive Committee challenged different critical days, starting with Covid-19, the local and internal problems as well as the financial inflation that hit Lebanon. Across all these, the Executive Committee resisted and achieved successful results.

Thank you again.

All the best for the new Executive Committee for May 2022 - May 2024:

President : Dr. Mohamad Moussa
Vice President : Dr. Khalil Armach
Secretary : Dr. Mohamad Jose Hejase
Treasurer : Dr. Zareh Kassardjian
Members : Dr. Alan Khalaf
Dr. Wael Ghandour
Dr. Zahi Abou Rjeily
Dr. Hussein Fayad Issa
Dr. Ramy Wajih Nasr

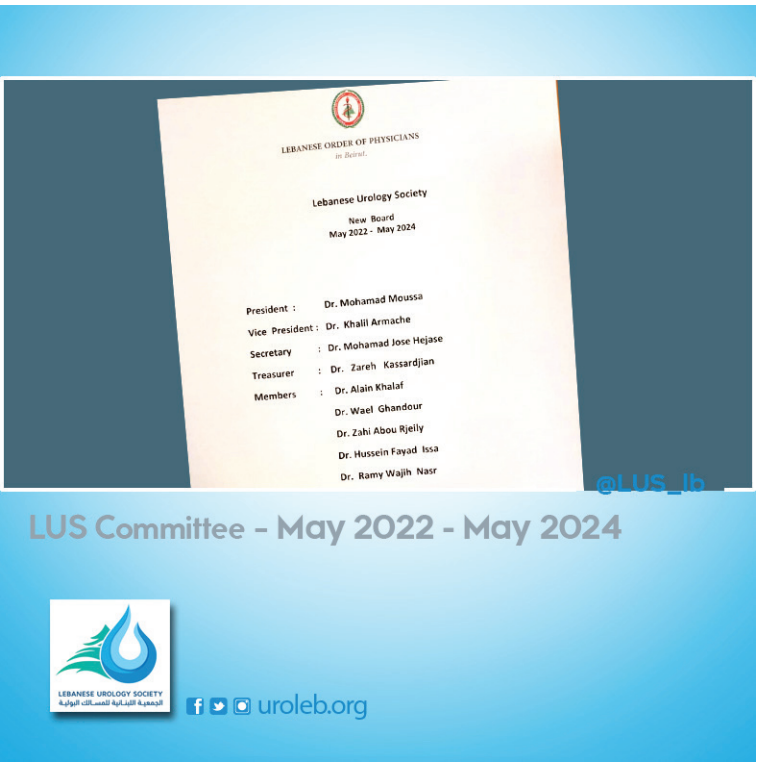

Dear Colleagues,

It is with all my pleasure to introduce the new board work plan of the Lebanese Urology Society (LUS). Our society is well known to teach with creativity and dedication.

As all know, we are grappling with a difficult time in Lebanon due to the current situation. As new president of the LUS, I will try to set plans with the new board members to pass this hard time and to ensure the highest academic achievement. I am always saying that 'Any kind of crisis can be good. It wakes you up'.
The LUS will continue to be recognized for its continuous scientific work and support of all Urologists.

I resume our work plan with 5 points:
- Continue Educational workshops and conferences
- Resolving Clinical practice problems
- Supporting Research in Urology
- National and International Communication
- Support our residents during their training LUS continues to advance its mission

Thank you.

Professor Mohamad A. Moussa
President

NCCN Guidelines add PSMA-PET imaging modalities for prostate cancer

NCCN Guidelines Updated to Include PSMA-PET Imaging. Posted online September 13, 2021

The NCCN has added Ga 68– and F 18–based PSMA-PET imaging modalities to its clinical practice guidelines for prostate cancer.
"The updated guidelines will encourage clinicians to use PSMA-PET as a primary imaging modality in patients and will deliver the benefit of a more streamlined approach.
According to the release, "The NCCN panel has recognized the increased sensitivity and specificity of PSMA-PET tracers, compared to conventional imaging (CT, MRI) for detecting micrometastatic disease, at both initial staging and biochemical recurrence. The updated guidelines state that the NCCN Panel does not feel that conventional imaging is a necessary prerequisite to PSMA-PET and that PSMA-PET/CT or PSMA-PET/MRI can serve as equally effective, if not more effective front-line imaging tools for these patients."1

In December 2020, the FDA approved Gallium 68 PSMA-11 (Ga 68 PSMA-11) as the first PSMA-PET imaging agent approved for prostate cancer.
In May 2021, the FDA approved the PSMA PET imaging agent piflufolastat F 18 (Pylarify) for identifying suspected metastasis or recurrence of prostate cancer.

Risk factors for increased stent-associated symptoms after ureteroscopy for stones

AUA conference, May 20, 2022

STUDY FINDINGS: patient factors related to pain intensity, increasing age was associated with less pain, history of prior chronic pain, history of severe pain with a past stent insertion, history of depression symptoms, all were associated with increasing pain.

Tislelizumab plus nab-paclitaxel shows promise in high-risk NMIBCC

1. Hu H, Niu Y, Wang H, et al. Update of TRUCE-02: an open label, single-arm, phase 2 study of tilelizumab combined with nab-paclitaxel for high-risk non-muscle-invasive urothelial bladder carcinoma (HR-NMIBC) which is not completely resectable. Presented at: 2022 American Urological Association Annual Meeting; May 13-16, 2022; New Orleans, LA. Abstract MP59-19.

Initial findings from the phase 2 TRUCE-02 study shared during the 2022 AUA Annual Meeting showed promising activity with the combination of tislelizumab and nab-paclitaxel (Abraxane) in patients with high-risk non–muscle invasive bladder cancer (HR-NMIBC), regardless of PD-L1 expression.1

In the study, an open-label, single-arm, phase 2 study (NCT04730232), there was a complete response (CR) rate of 62.5%, which met the primary end point of the trial.

Previously,The phase 2 KEYNOTE-057 trial (NCT02625961) also demonstrated efficacy and safety with pembrolizumab monotherapy as antitumor treatment in Bacille Calmette-Guérin–unresponsive patients with HR-NMIBC.
In this trial, patients with HR-NMIBC that cannot be completely resected received 3 or 4 cycles of tislelizumab on day 1 and nab-paclitaxel on day 2, both at 200 mg intravenously every 3 weeks followed by a multipoint resection biopsy. The primary end point is the patients' CR rate, and secondary end points included cystectomy-free survival, duration of response, and the number and severity of AEs.

So far, 51 patients have been enrolled in the TRUCE-02 study; 32 patients have completed treatment of 3 or 4 cycles and met the primary end point. There were 20 patients of the 32 total who achieved CR, with a CR rate of 62.5%. Furthermore, 4 patients (12%) experienced a partial response (PR), and 5 (16%) had stable disease. Progressive disease was observed in 3 patients (9%). Currently, 4 patients (12.5%) have proceeded to cystectomy after treatment.

Positive PD-L1 expression was found in 12 (50%) out of the 24 patients who had response of either CR or PR. Three patients out of 8 (38%) who were unresponsive to treatment had positive PD-L1 expression. However, homologous recombination repair mutations may predict favorable prognosis, according to the investigators.

Pre-existing Castration-resistant Prostate Cancer–like Cells in Primary Prostate Cancer Promote Resistance to Hormonal Therapy

Platinum Priority – Prostate Cancer, journal of European urology may 2022.

Hormonal therapy targeting the androgen receptor inhibits prostate cancer (PCa), but the tumor eventually recurs as castration-resistant prostate cancer (CRPC). The objective of the study was to understand the mechanisms by which subclones within early PCa develop into CRPC.

The method was by single-cell RNA sequencing to identify subpopulations destined to become either CRPC-adeno or small cell neuroendocrine carcinoma (SCNC).

The researchers identified a small fraction of highly plastic CRPC-like cells in hormone-naïve early PCa and demonstrated its correlation with biochemical recurrence and distant metastasis, independent of clinical characteristics. they showed that progression toward castration resistance was initiated from subtype-specific lineage plasticity and clonal expansion of pre-existing neuroendocrine and CRPC-like cells in early PCa.

Conclusions: CRPC-like cells are present early in the development of PCa and are not exclusively the result of acquired evolutionary selection during androgen deprivation therapy. The lethal CRPC and SCNC phenotypes should be targeted earlier in the disease course of patients with PCa.

What Happens to the Preserved Renal Parenchyma After Clamped Partial Nephrectomy?

2022 European Association of Urology

The Objective was to compare the histologic chronic kidney disease (CKD)score of renal parenchyma before and years after PN, and to explore factors associated with CKD-score increase and glomerular filtration rate (GFR) decline.

Conclusions: Within the context of conventional, limited durations of ischemia, histo logic deterioration of preserved parenchyma after PN appears to be primarily due to pre-existing medical comorbidities such as hypertension, diabetes mellitus, or chronic kidney disease rather than ischemia. In contrast, the type and duration of ischemia did not correlate with histologic changes after PN, suggesting that ischemia insult had only limited impact on parenchyma deterioration.

POSTPONED TILL JULY 2022

EAU22 - AMSTERDAM